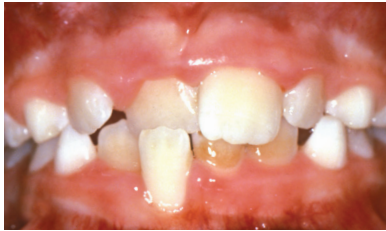
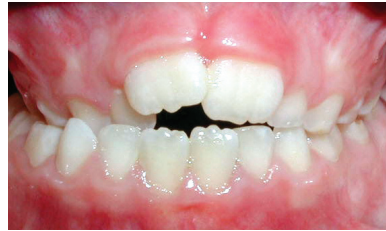
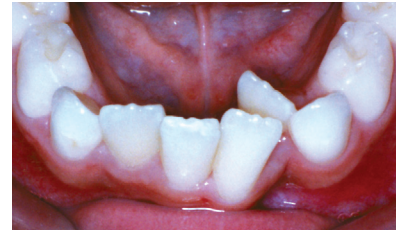Problems to Watch for in Seven Year Olds



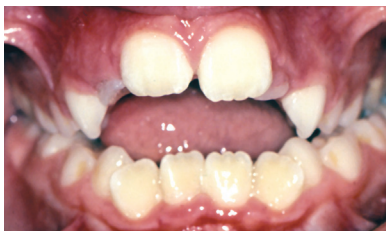Anterior Crossbite



Posterior Crossbite

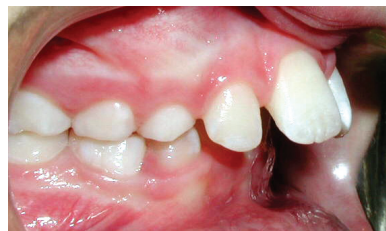

Crowding

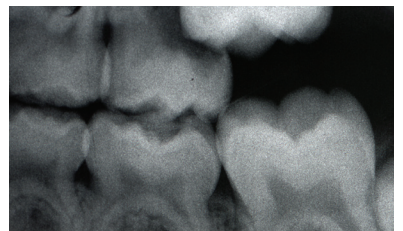


Open Bite

An open bite is usually due to an oral habit.

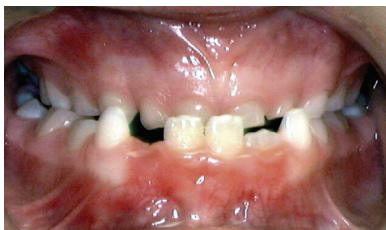

Protrusion

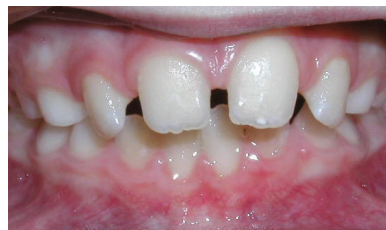

Ectopic Eruption

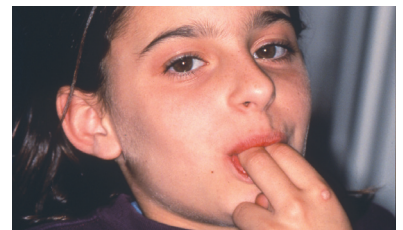Ectopically erupting maxillary molar.



Complete Class III



Diastema



Oral Habits

Malocclusions, like those illustrated above, may benefit from early diagnosis and referral to an orthodontic specialist for a full evaluation.

As a dental health professional, you hold an important position on the dental team. You are often the first to see a patient and first to recognize that the patient may have an orthodontic problem.

The orthodontist's goal is to provide each patient with the most appropriate treatment at the most appropriate time. By working together, the dental team can achieve results for patients that cannot be produced alone.